EVALUATION OF AN ADRENAL INCIDENTALOMA

Jyotika Fernandes, M.D.

Professor,
Div of Endocrinology, Department of Medicine, MUSC
Endocrine Section Chief Ralph H Johnson VA Charleston, SC

Learning Objectives

Prevalence of adrenal incidentalomas

Differential diagnosis

Address two key questions

- Is this mass benign or malignant
- Is the adrenal mass secreting hormones - functional or nonfunctional

When is surgery indicated

Multidisciplinary team for effective management

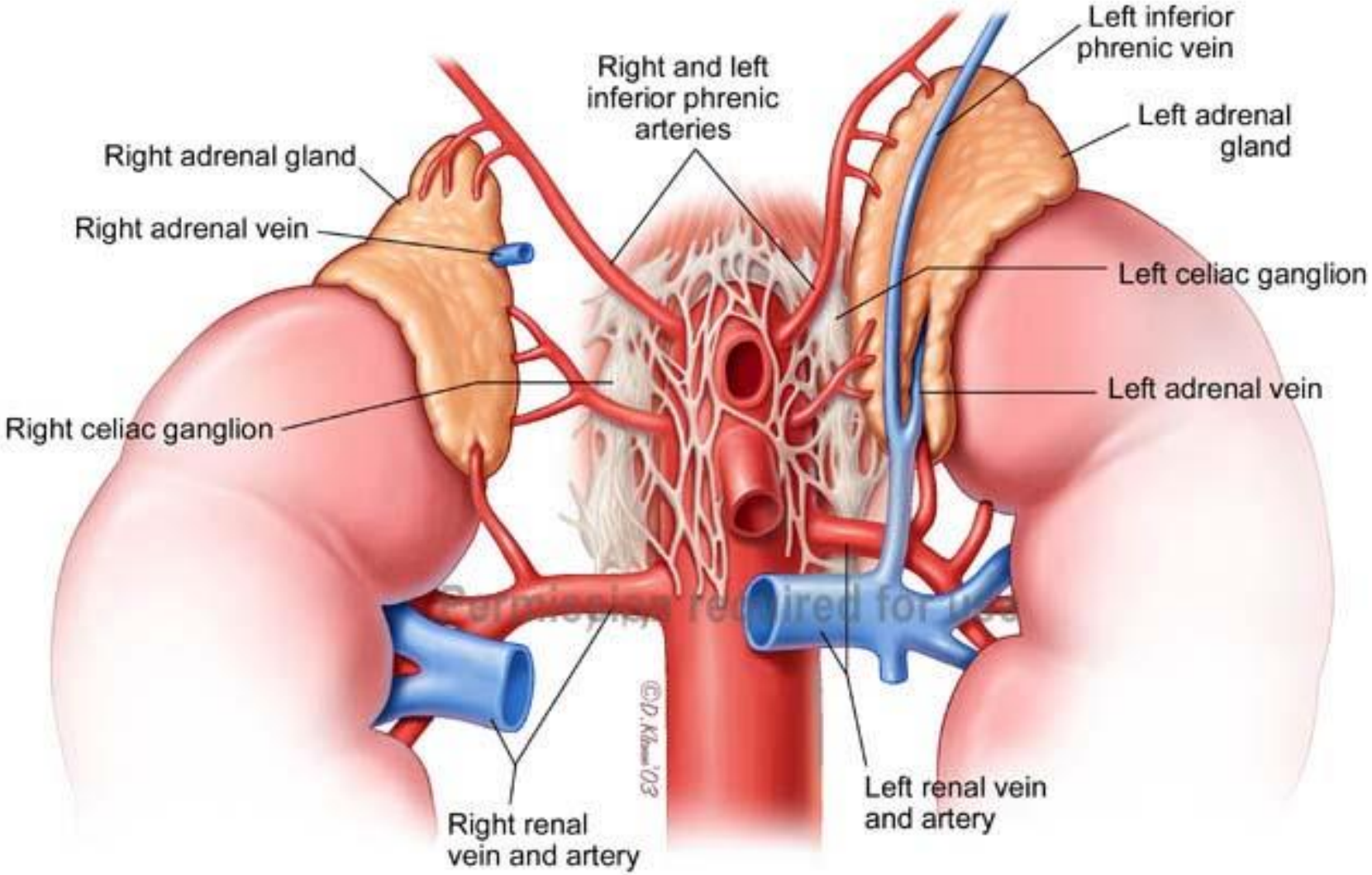
Right and left
inferior phrenic
arteries
Left inferior
phrenic vein
Left adrenal
gland
Right adrenal gland
Right adrenal vein
Left celiac ganglion
Left adrenal vein
Right celiac ganglion
Right renal
vein and artery
Left renal vein
and artery

Copyright © The McGraw-Hill Companies, Inc. Permission required for reproduction or display.

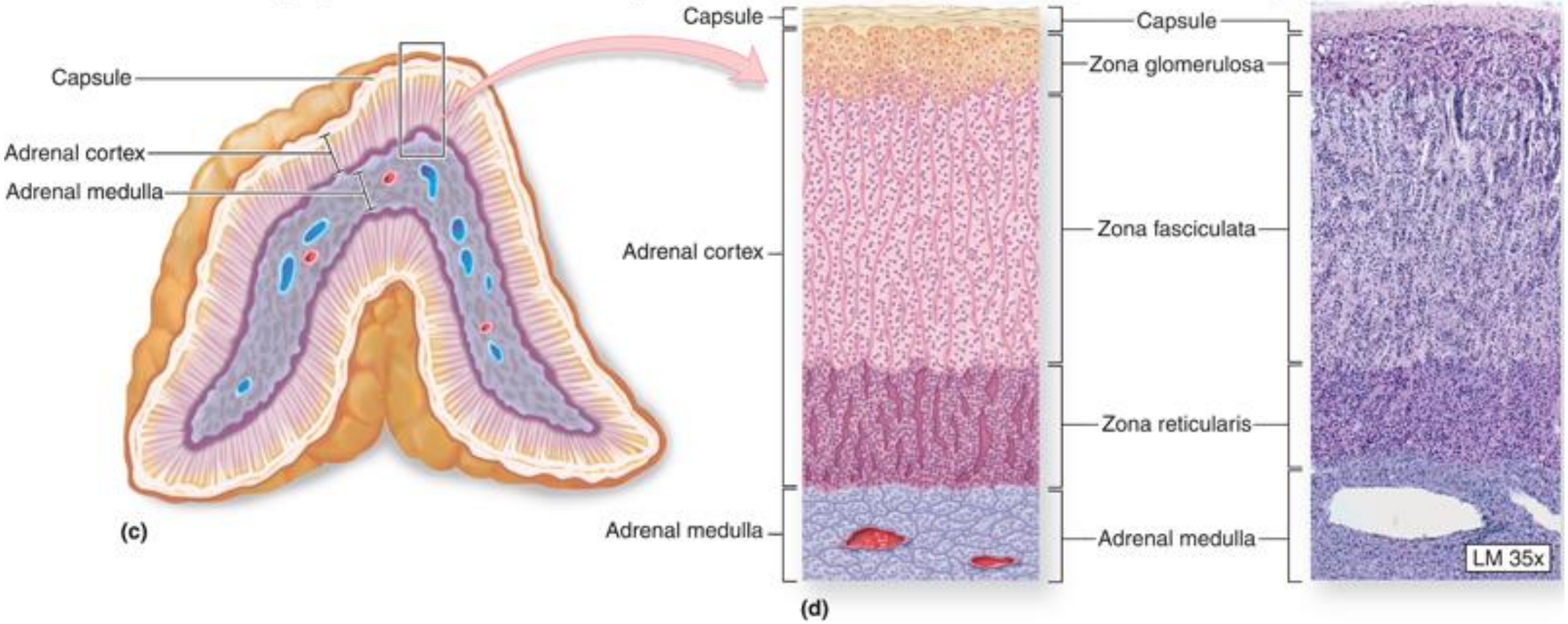

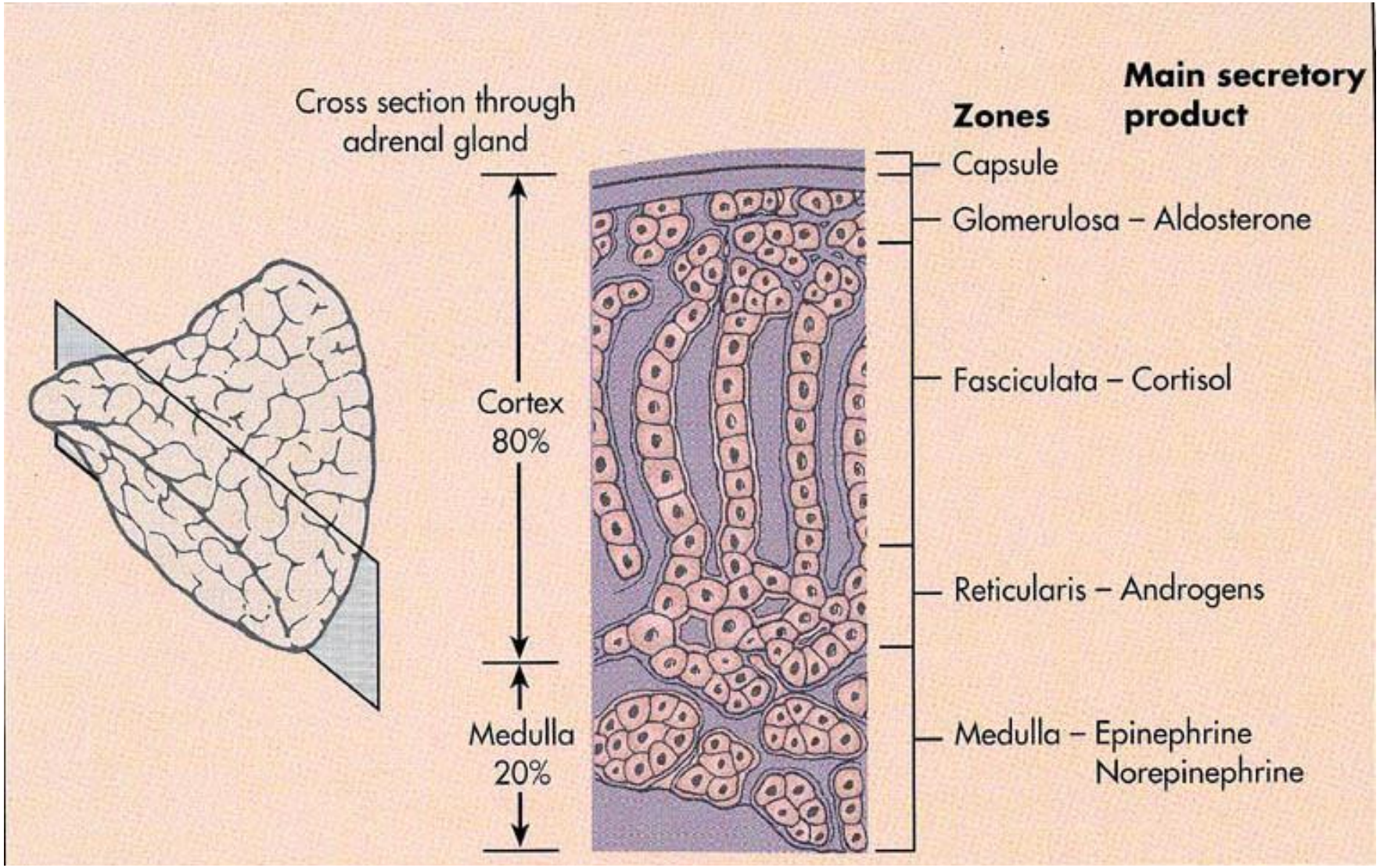
Cross section through adrenal gland
Cortex 80%
Medulla 20%
Zones
Main secretory product
Capsule
Glomerulosa – Aldosterone
Fasciculata – Cortisol
Reticularis – Androgens
Medulla – Epinephrine
Norepinephrine

Normal Adrenal Radiology CT scan

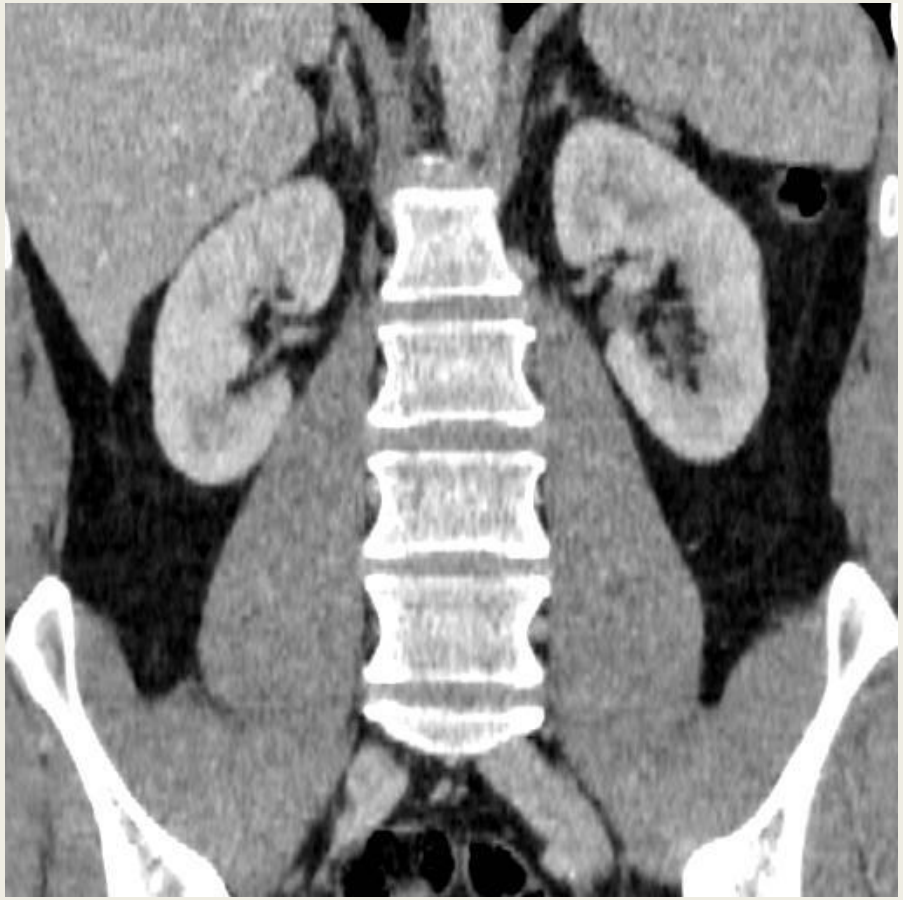

HIGH RESOLUTION IMAGING

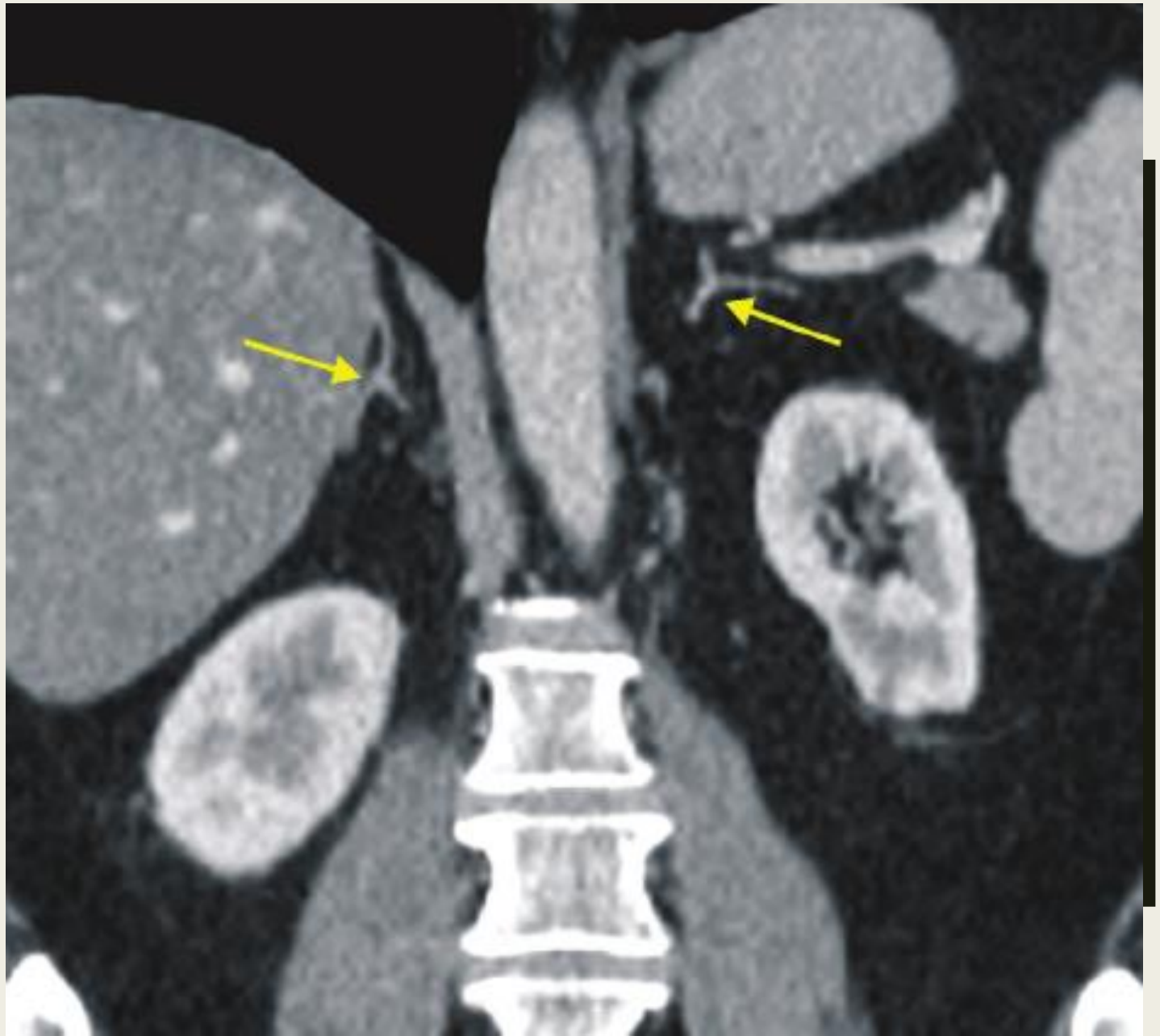

Case – Mrs. G ,53-year-old white lady comes to ER with abdominal pain.
No history of hypertension .
Labs – Potassium 4.5 m Eq /L

She gets a CT scan done as part of work up.

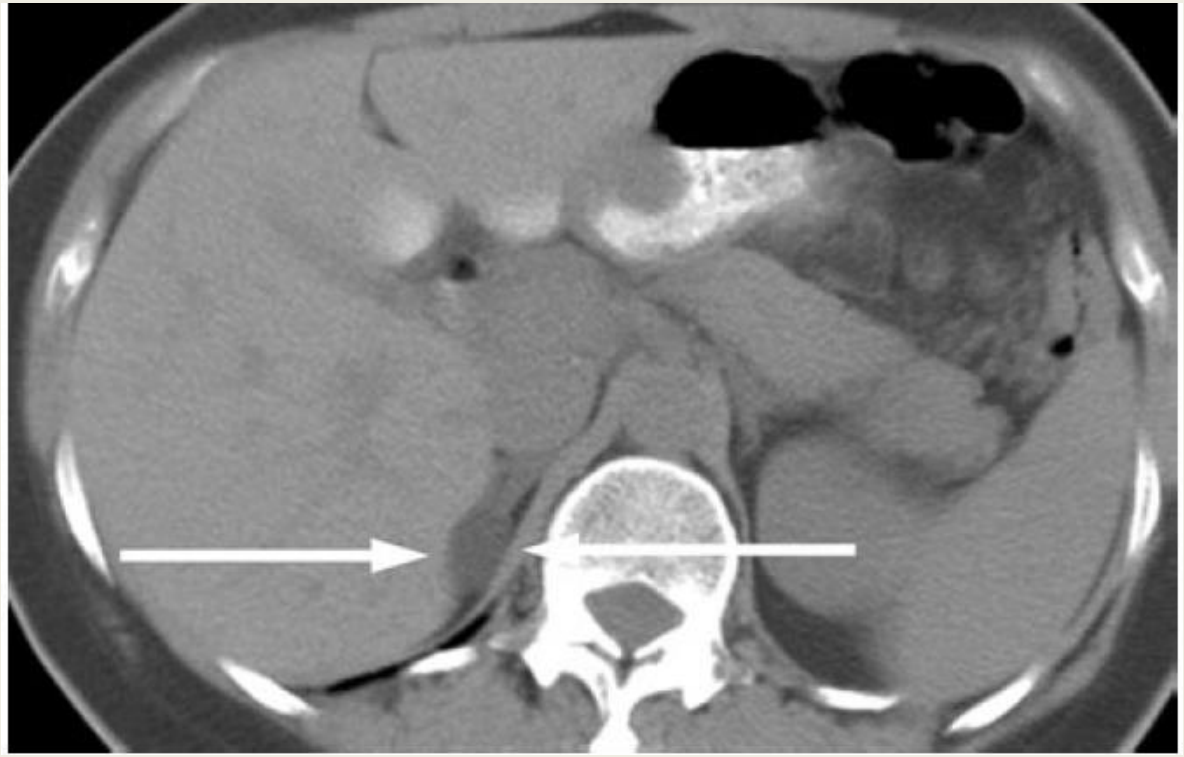

A 2.1-cm left adrenal mass was discovered on computed tomography (CT).

Case – 53-year-old lady comes to ER with abdominal pain . Vital signs stable.
No history of hypertension .
Labs – Potassium 4.5 mEq/l

She gets a CT scan done as part of work up.

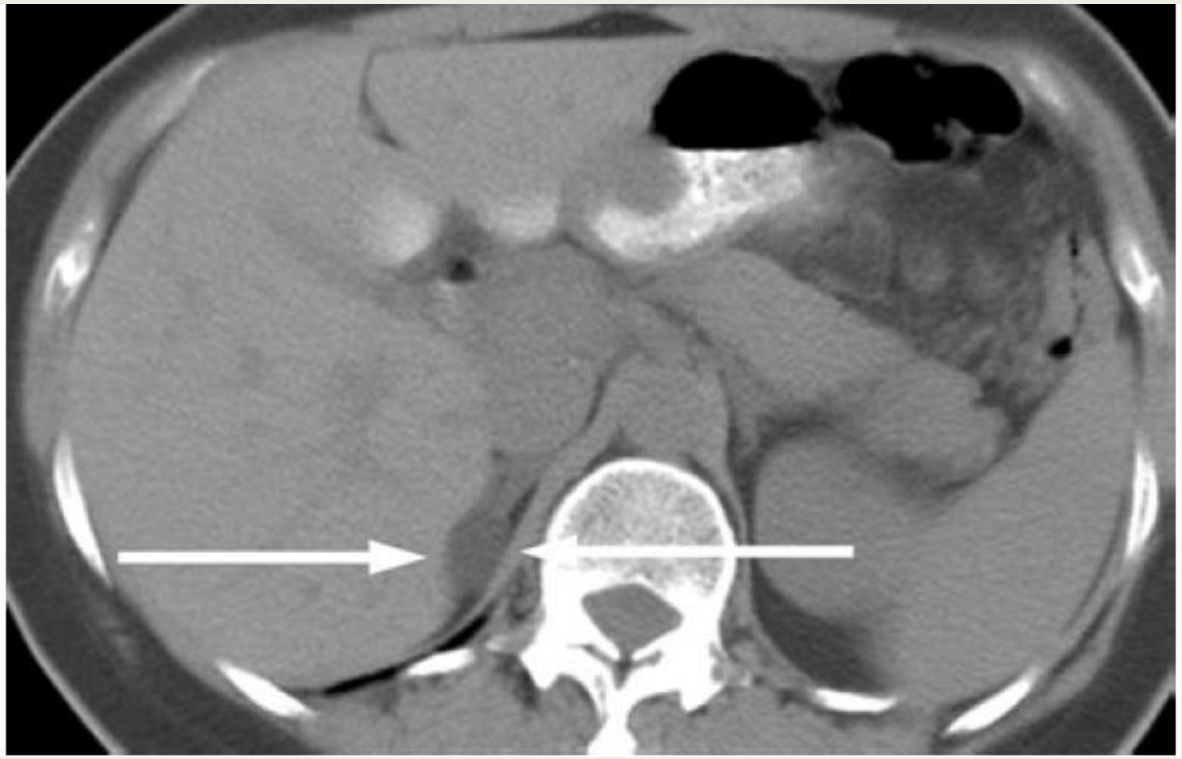

A 2.1-cm left adrenal mass was discovered on contrast-enhanced computed tomography (CT).

"Sorry..... we don't know the cause of your abdominal pain"

"Incidentally, you have an adrenal tumor "

Adrenal Incidentaloma

- Adrenal "incidentaloma" is an adrenal mass (generally 1 cm or more) discovered during the radiological examination performed for indications other then an evaluation for adrenal disease.

- Increase use in radiological imaging procedures resulted in this clinical dilemma.
- Raises uncertainty and confusion in doctors and patients
- Significant resources and manpower implications

Young WF Jr, NEJM 2007; 356:601-610

A '*disease*' of ageing- Autopsy data from 57,262 subjects

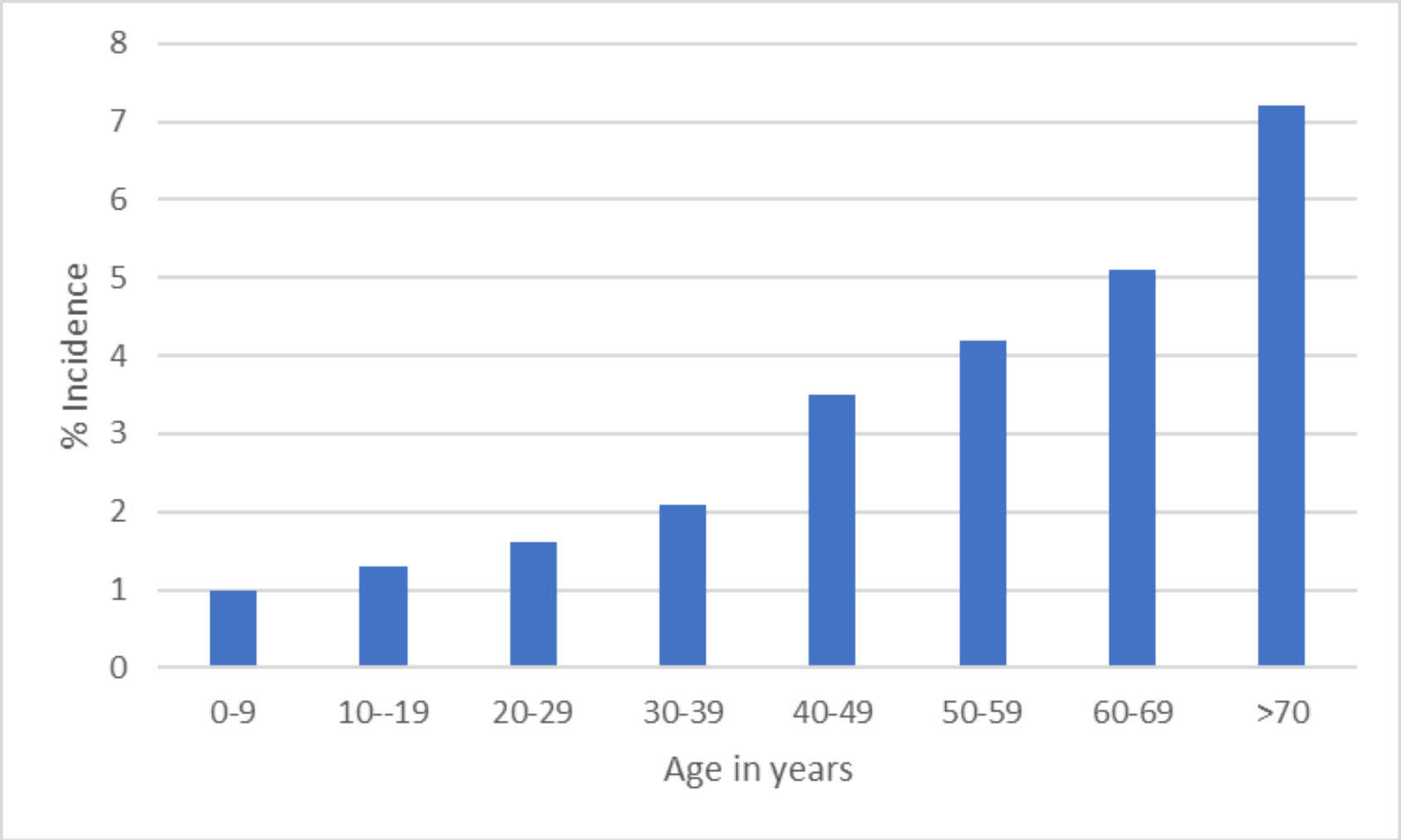

TerzaloM, European Journal of Endocrinology,2011 164 851–870

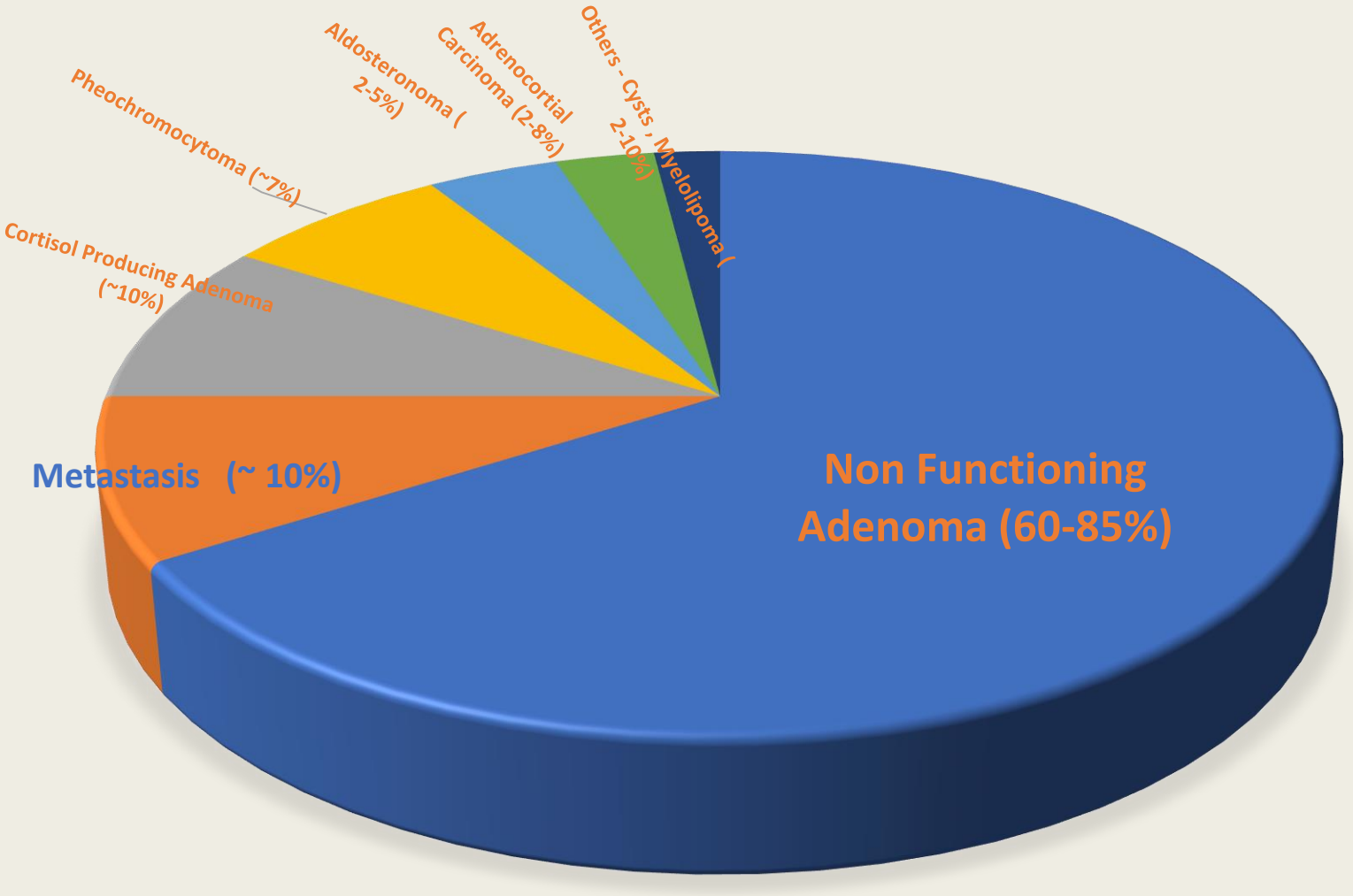

t

TerzaloM, European Journal of Endocrinology,2011 164 851–870

Adrenal Incidentaloma

- Is the mass Malignant ?

Adrenal Incidentaloma

- Is the mass Malignant ?
  - *Is it primary or metastasis ?*

Adrenal Incidentaloma

- Is the mass Malignant ?
  - *Is it primary or metastasis ?*
- Is the mass functional?

Adrenal Incidentaloma

- Is the mass Malignant ?
  - *Is it primary or metastasis ?*

- Is the mass functional?
  - ***15% of adrenal incidentaloma are functional***
  - ***Autonomous Cortisol secretion*** *(previously called subclinical Cushing's)*
  - ***Pheochromocytoma***
  - ***Primary Aldosteronism*** *(only if hypertension / hypokalemia)*

Work up of Adrenal Incidentaloma

- All patients need an imaging procedure
  - ***Non-Contrast CT usually first choice***
    - Radiodensity (Hounsfield units)
    - Size , Homogeneity
- CT with delayed contrast washout
- *MRI –chemical shift*
- *PET CT*

Imaging : Non-Contrast CT

	Favoring Surgery	Favoring Follow up
Tumor size	>6 cm	<4 cm
Imaging Morphology	Heterogeneous mass with irregular margins	Homogenous with smooth border
CT Hounsfield Units	>10 (20) HU	<10 (20) HU Lipid rich Sensitivity ~100 % No Follow up

Hounsfield scale- Quantification of radiodensity : Air -1000, Fat -120, Water 0, Bone +400

Other Imaging findings to help differentiate Malignant and Benign Adrenal Incidentalomas

	Findings				
*Type of incidentaloma**	*Size*	*Attenuation on unenhanced CT*	*Rapidity of washout of contrast media on enhanced CT*	*Appearance on MRI (out-of-phase image)*	*Growth rate*
Lipid-rich adrenal adenoma	< 3 cm	≤ 10 HU	Rapid washout	Signal loss	Size usually stable
Lipid-poor adrenal adenoma	< 3 cm	> 10 HU	Rapid washout	No signal loss	Size usually stable
Adrenocortical carcinoma	Usually > 5 cm	> 10 HU	No rapid washout	No signal loss	Usually significant growth
Pheochromocytoma	Variable size	> 10 HU	No rapid washout	No signal loss	Slow growth
Metastasis	Variable size	> 10 HU	No rapid washout	No signal loss	Usually significant growth

**—Listed by most to least common.*

CT = computed tomography; MRI = magnetic resonance imaging.

Benign or Malignant ?

- Poor evidence regarding second- or third-line imaging being superior to CT

- Favoring benign lesion
  - *Loss of signal intensity on out of phase MRI chemical shift imaging*
  - *Contrast enhanced washout CT scan (>absolute washout ,delayed scan at 15 minutes)*
  - *Absent FDG uptake on FDG PET (or uptake less than liver)*

DinnesJ, EJE 2016;175,R51-64
Hong AR, EJE 2017; 177, 475-485

Non contrast HU distribution of adrenal masses in different groups.

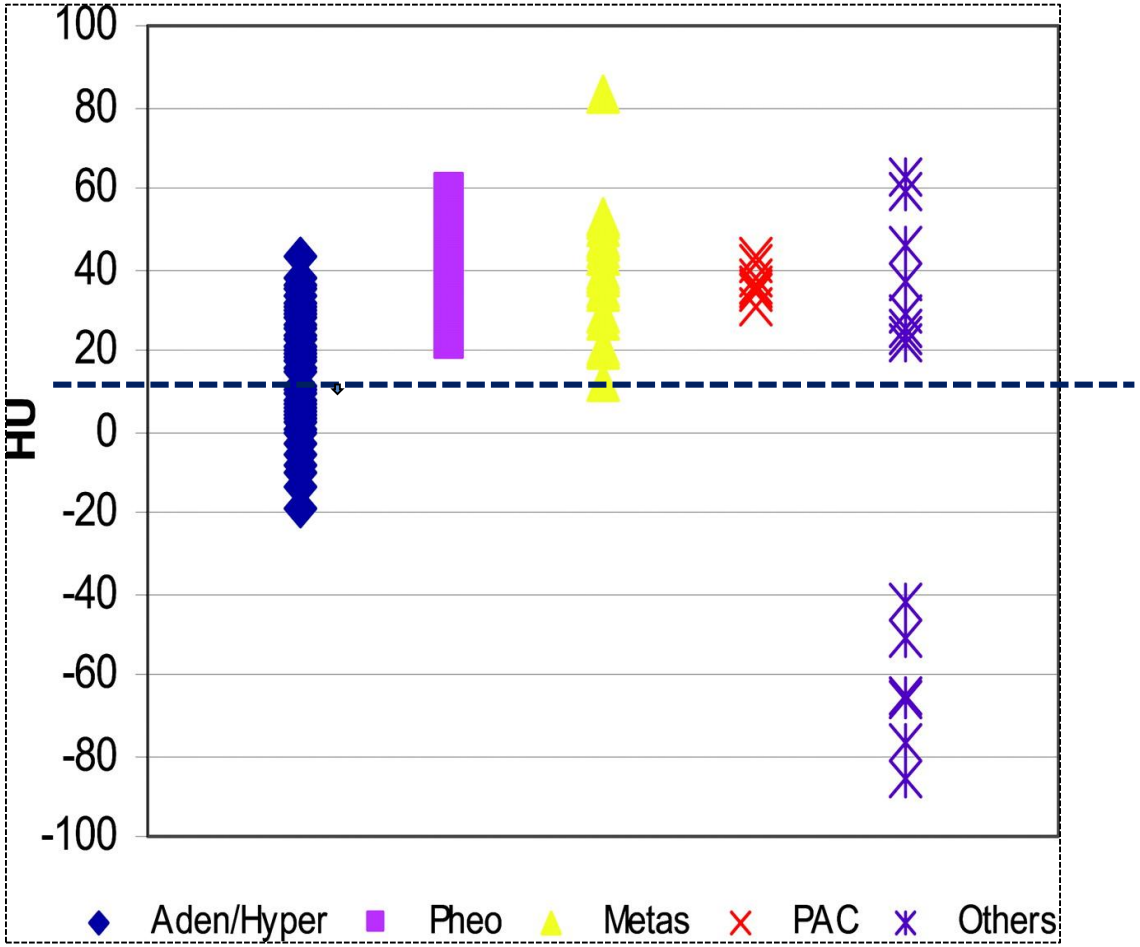

The Journal of Clinical Endocrinology & Metabolism, Volume 90, Issue 2, 1 February 2005, Pages 871–877,

Benign or Malignant ? Tumor size

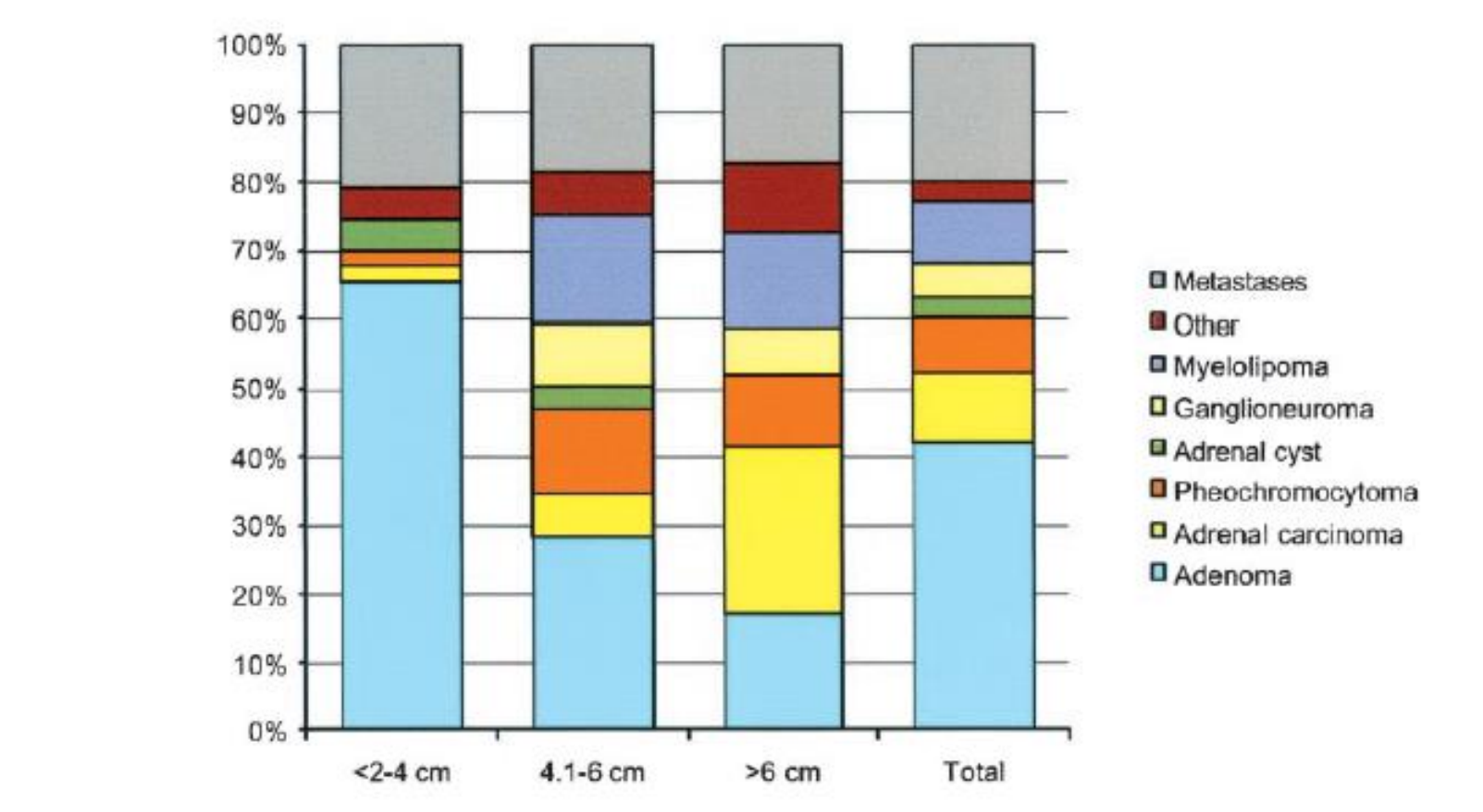

F. Mantero *et al.*: *J Clin Endocrinol Metab* 85:637–644, 2000

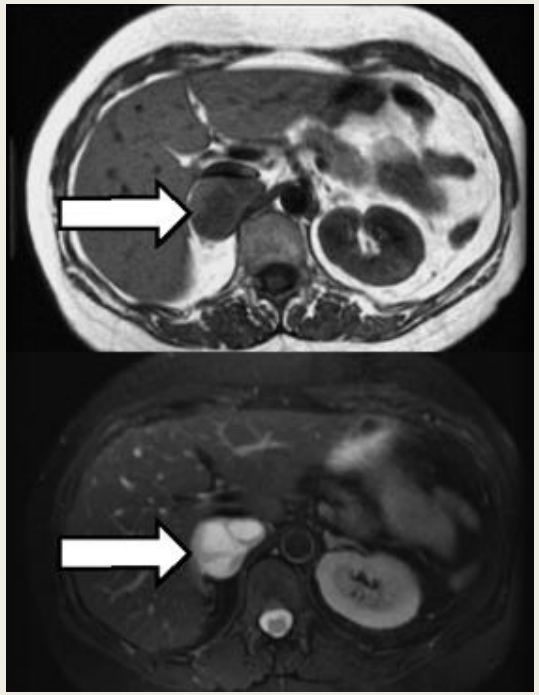

<u>Adenoma:</u>
Round, homogeneous
Smooth contour
<4cm
<10 HU
Isointensity with liver
Rapid contrast washout

<u>Pheochromocytoma:</u>
>20 HU
Increased vascularity
Delayed contrast washout
Heterogeneous
High signal intensity on
T-2 Weighted MRI

<u>Carcinoma:</u>
Irregular
Heterogeneous
Calcifications
>4cm
>20 HU
Delayed contrast washout
Hypodense to liver

Case – Mrs. G ,53-year-old white lady comes to ER with abdominal pain.
No history of hypertension.
Labs – Potassium 4.5 m Eq /L

She gets a CT scan done as part of work up.

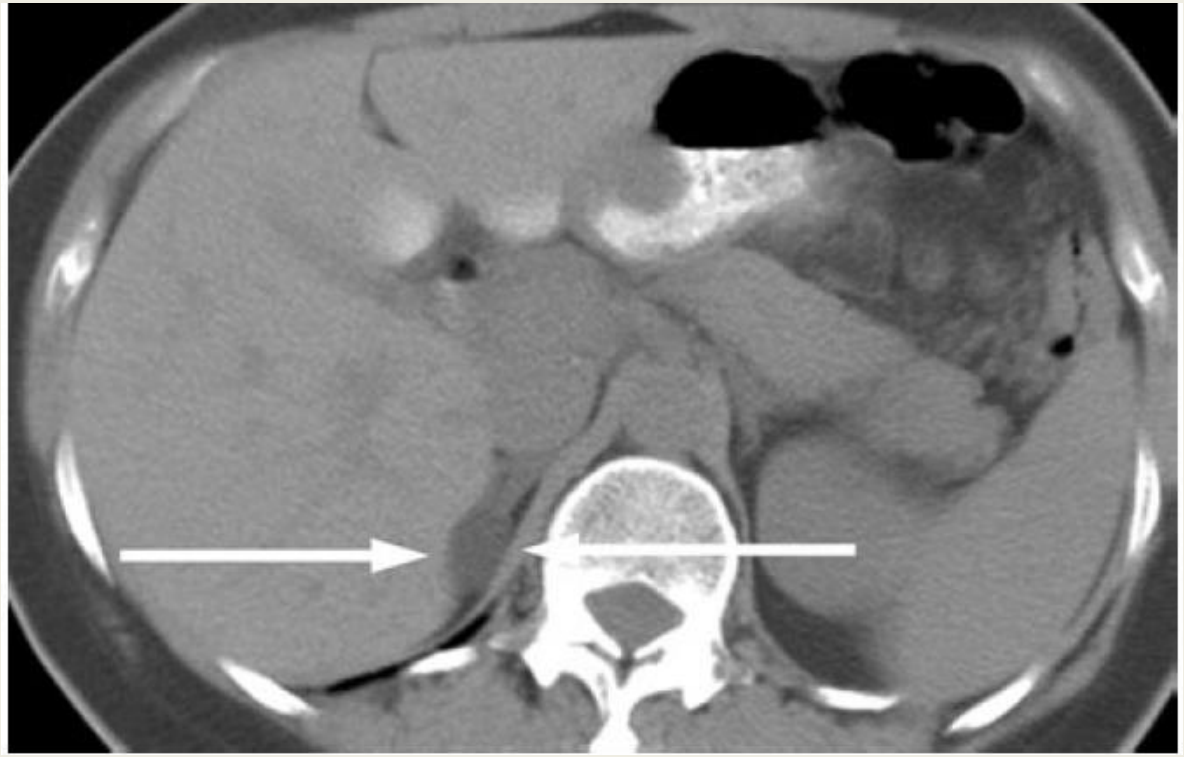

A 2.1-cm left adrenal mass was discovered on computed tomography (CT).

Patient asks you – is this malignant ?

Case 1 – Mrs G ,53-year-old white lady comes to ER with abdominal pain
Vital signs stable. No history of hypertension .
Labs – Potassium 4.5 mEq/L

She gets a CT scan done as part of work up.

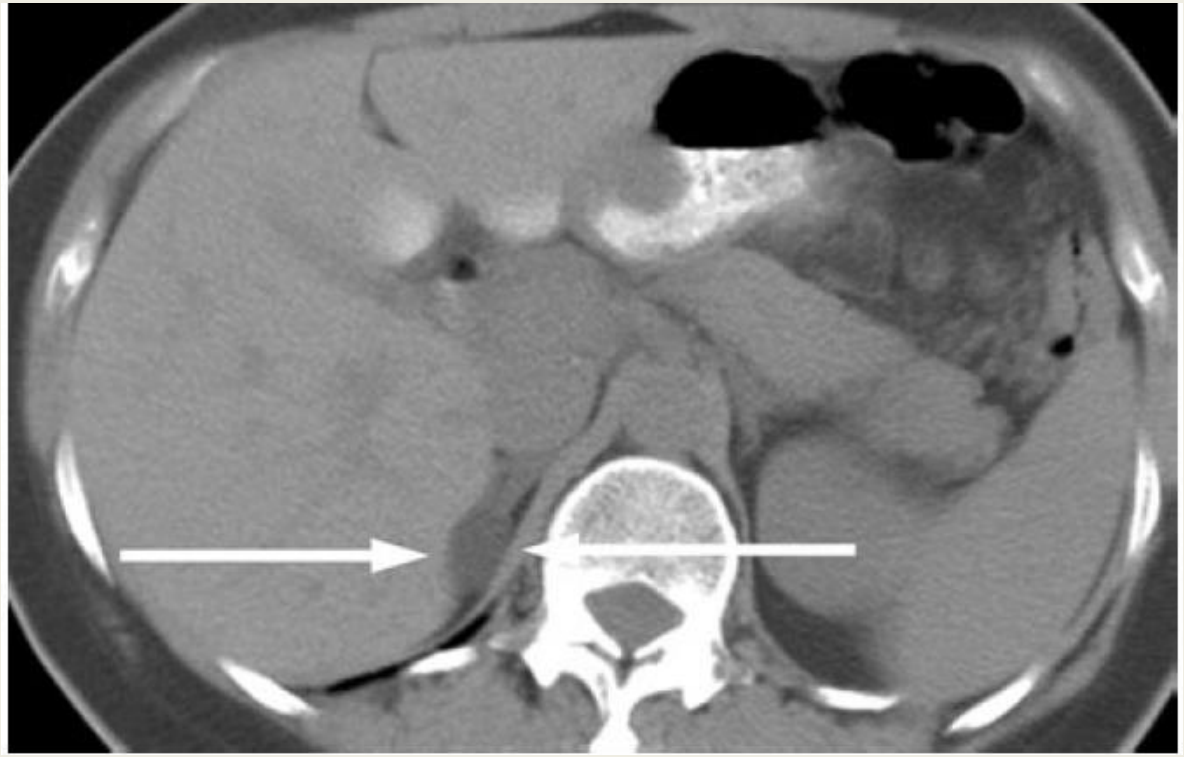

A 2.1-cm left adrenal mass was discovered
on contrast-enhanced computed tomography (CT).
Adrenal lesion of low attenuation
(6 HU), which is consistent with a lipid-rich adenoma.

No concerns for being malignant

Adrenal Cancer

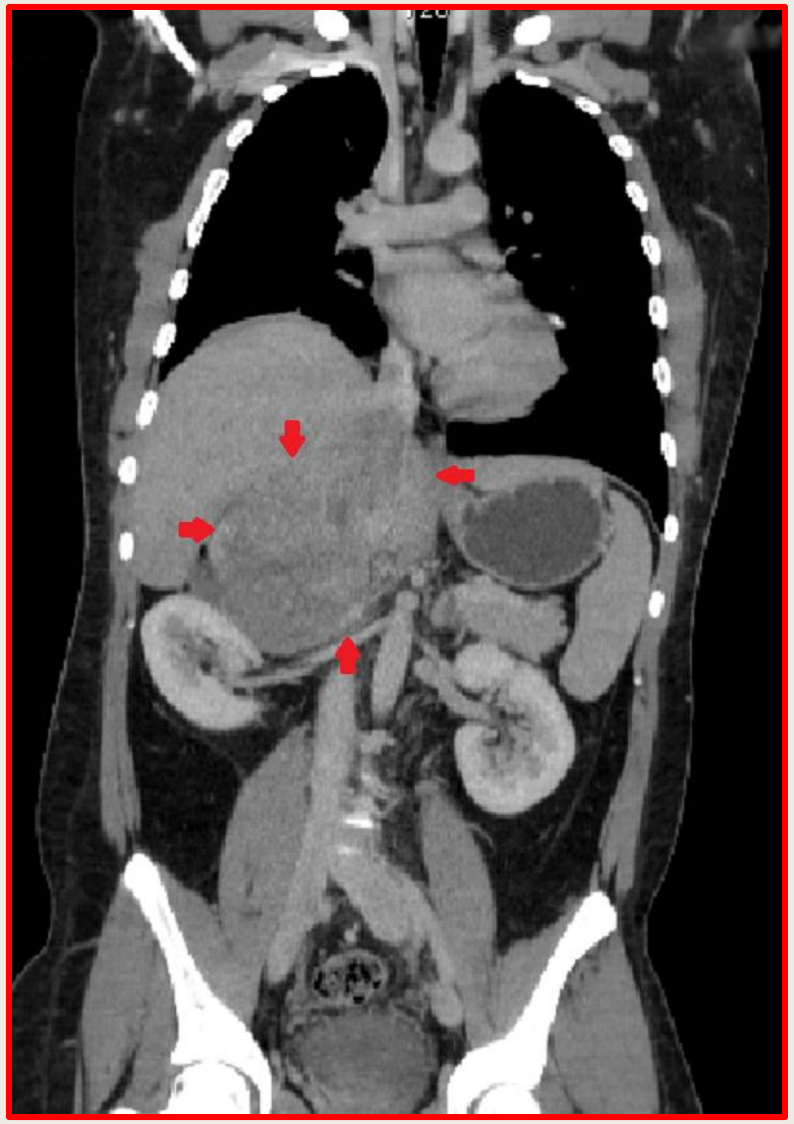

Hormonal evaluation

From least likely:

- Androgen producing tumors
- Aldosteronoma
- Pheochromocytoma
- Cushing's / Autonomous cortisol secretion syndrome

Hormonal evaluation

From least likely:

- Androgen producing tumors
- Aldosteronoma
- Pheochromocytoma
- Cushing's / Autonomous cortisol secretion syndrome

Imaging cannot reliably distinguish between functioning Or Non-functioning adenomas

Functioning or non -Functioning?

- Careful Evaluation and examination – S/S of hormone excess
- All pts to have 24-hour Urinary fractionated metanephrines or plasma metanephrines
- If malignancy or hyperandrogen : Sex Steroids
  - *DHEA-S, 17-OHP, Androstenedione (Testosterone /Estradiol)*
- If Hypertension or hypokalemia : Plasma Renin , Aldosterone
  - *PAC (ng/dl) / PRA ratio (ng/ml) >20*
  - *PAC = or > 15 ng /dl*
- What to do about cortisol hypersecretion??
  - *Avoid the term subclinical crushing's*

Screening

- Autosomal Cortisol secretion/ Cushing's (14%)
  - *1 mg overnight Dexa supp test*
  - *Midnight salivary*
- Pheochromocytoma (10%)
  - *Plasma Free Metanephrines*
  - *24 hr Ur Fractionated Metanephrines*
- Primary Aldosteronism or Conns (2%)
  - *PAC (ng/dl) / PRA ratio (ng/ml) >20*
  - *PAC = or > 15 ng /dl*
- Malignant potential – 41% non hormone secreting

CUSHING'S OR AUTONOMOUS CORTISOL SECRETION

Cortisol Hypersecretion
How to diagnose?

Cortisol Hypersecretion : How to diagnose?

- Clinical acumen important
- Test for Cushing's in patients with
  - *Unusual features for age*
  - *Pts with multiple /progressive features that are predictive of Cushing's syndrome*
  - *Patients with adrenal incidentaloma compatible with adenoma*
- Employ 2 of the 3 sensitive tests
  - *Urinary free Cortisol*
  - *Late night salivary Cortisol*
  - *1 mg Dex supp test*
- Late night salivary Cortisol has highest Sensitivity and Specificity

Nieman JCEM 2008,93:1526 & Elamin MB JCEM2008,93 1553

Potential predictive factors for cardiovascular morbidity, bone fractures, and infectious complications associated with autonomous cortisol secretion

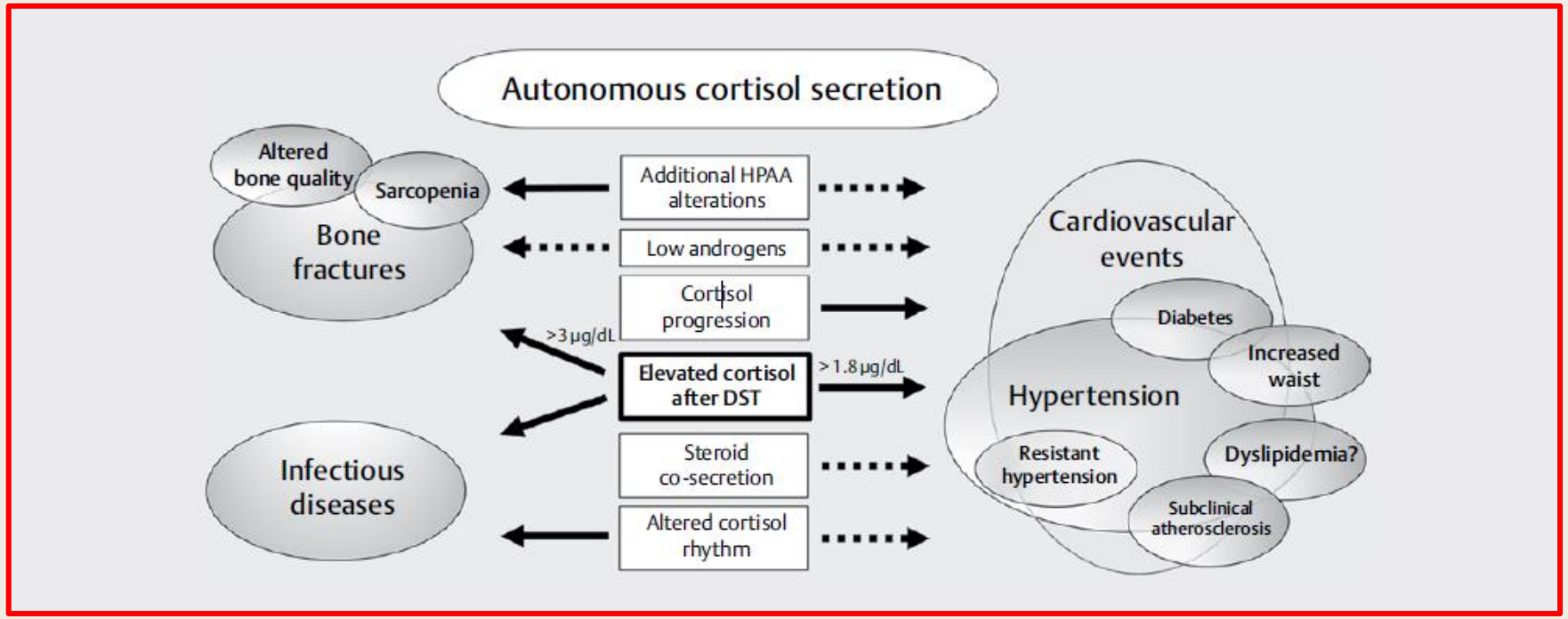

Di Dalmazi G. Adrenal Incidentaloma: Picking out … Exp Clin Endocrinol Diabetes 2019; 127: 178–184

1 mg Dexamethasone Supp test recommended



1 mg Dex suppression test interpretation
≤ 1.8mcg/dl EXCLUDES autonomous cortisol secretion

≥ 5mcg/dl CONFIRMS autonomous cortisol secretion

1.8-5 mcg/dl “POSSIBLE“autonomous cortisol secretion

European Endo Society guidelines , Fassnacht M, EJE 2016; 175: G1-34

PHEOCHROMOCYTOMA

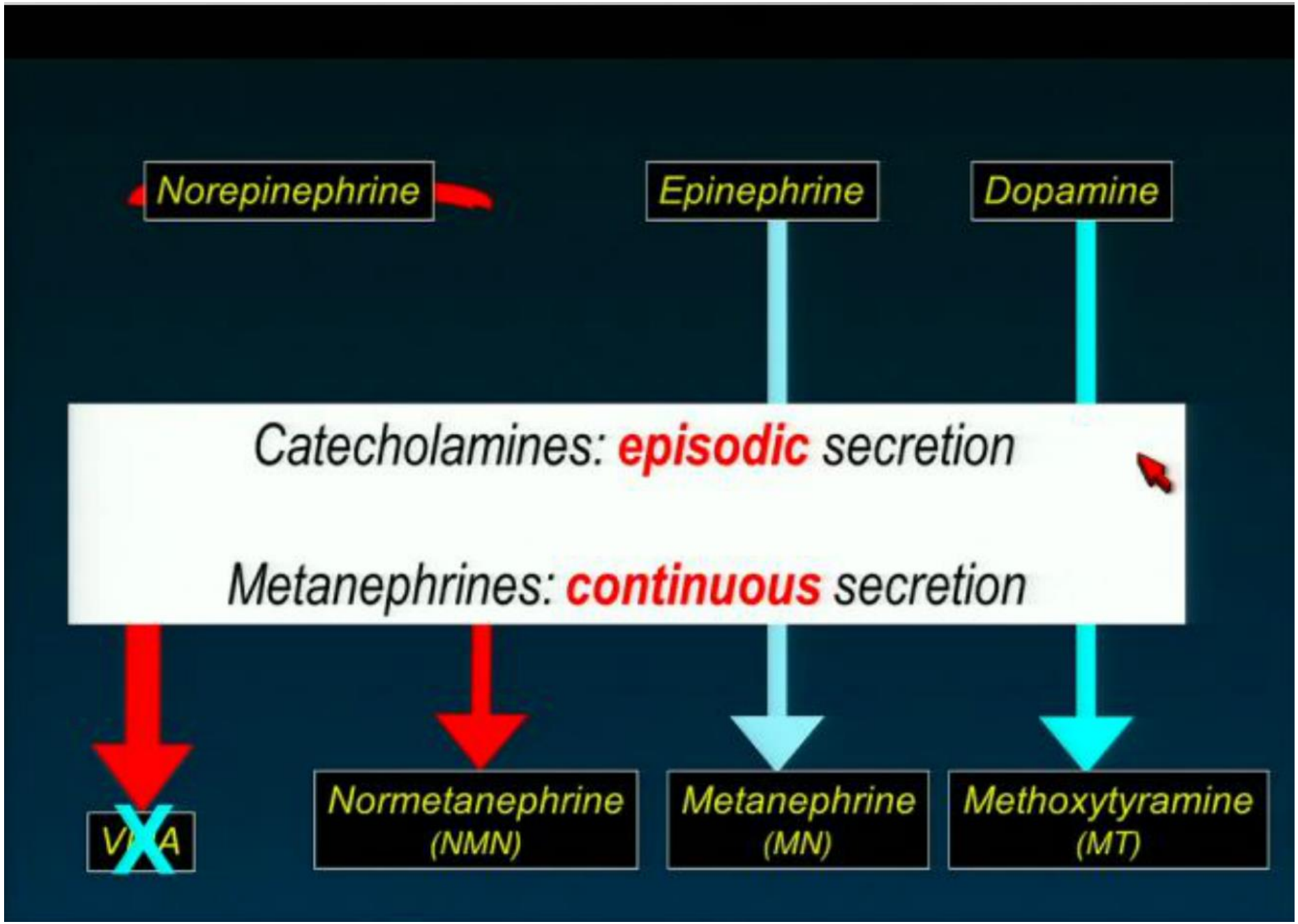
Norepinephrine
Epinephrine
Dopamine
Catecholamines: episodic secretion
Metanephrines: continuous secretion
VMA
Normetanephrine (NMN)
Metanephrine (MN)
Methoxytyramine (MT)

Clinical Presentation



Clinical Presentation

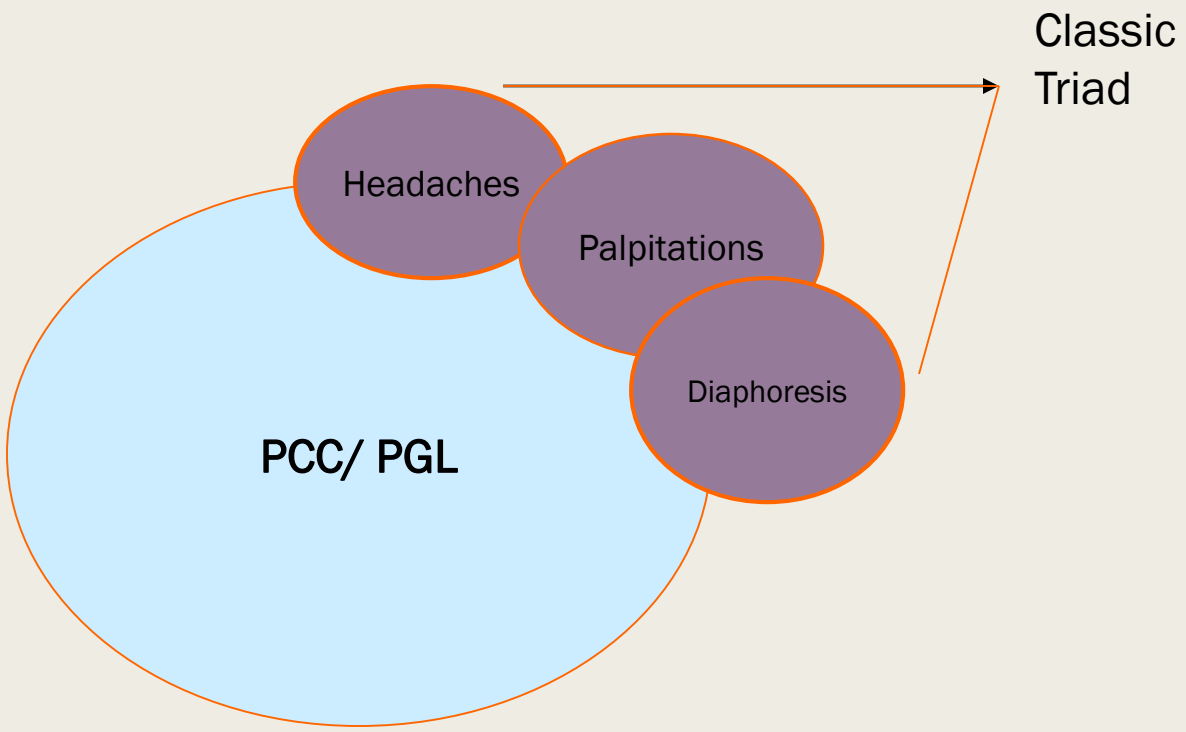

Clinical Presentation

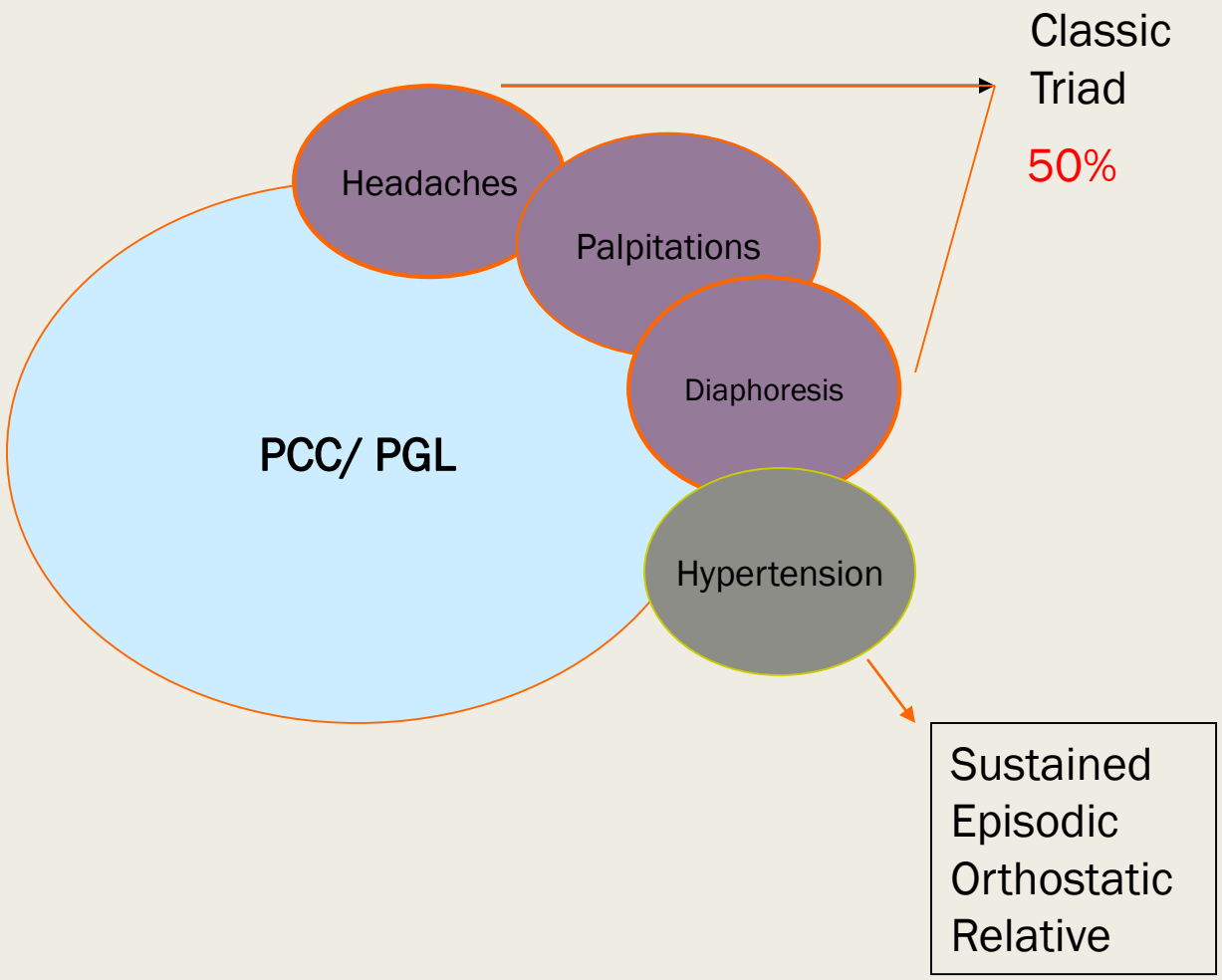

Clinical Presentation

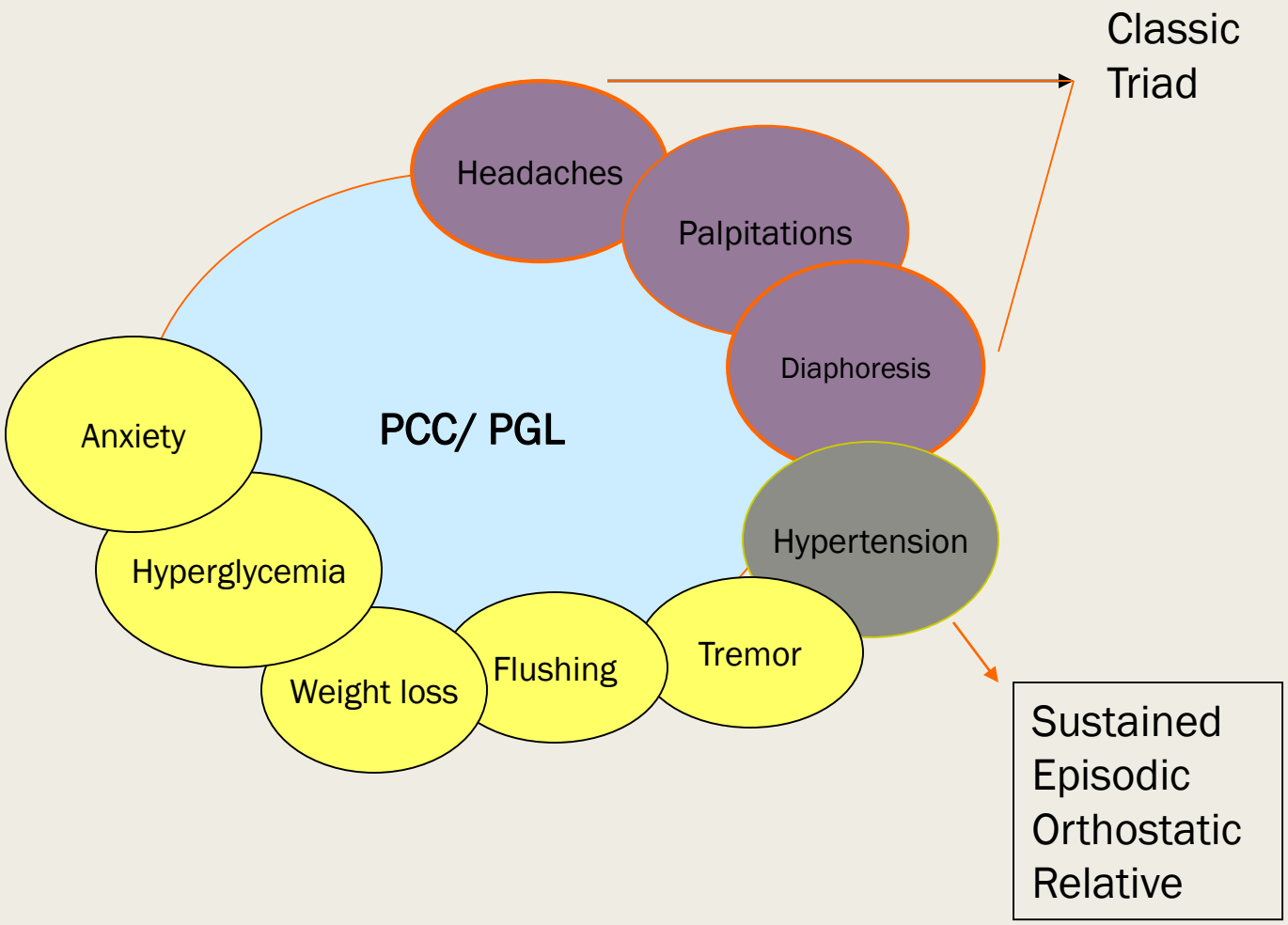

Clinical Presentation

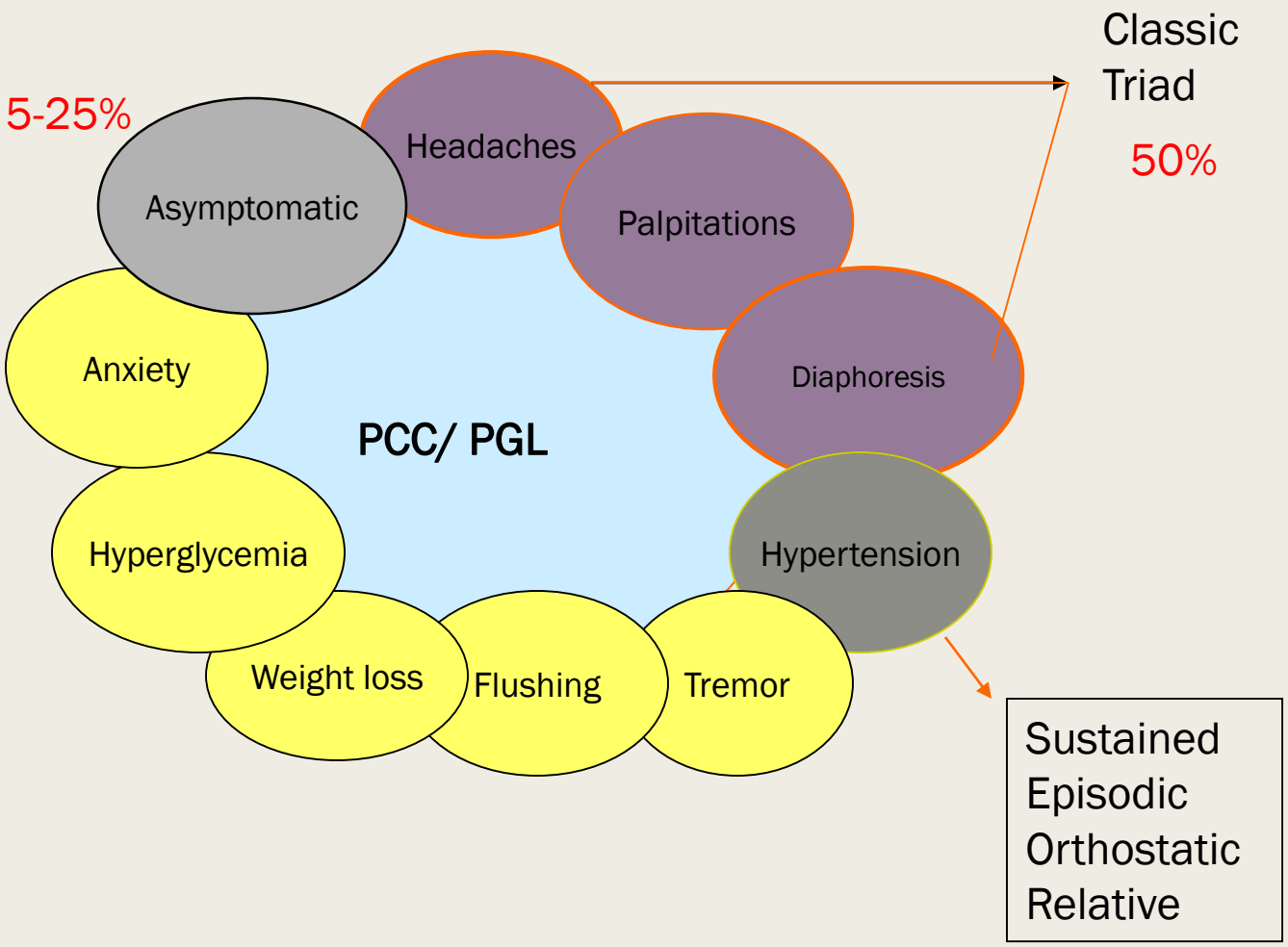

Sensitivity and specificity of biochemical tests for diagnosis of pheochromocytoma

	Sensitivity	Specificity
Plasma-free metanephrine	99	89
Plasma catecholamine	84	81
Urinary catecholamine	86	88
Urinary-fractionated metanephrines	97	69
Urinary total metanephrine	77	93
VMA	64	95

Jacques W M Lenders, Lancet 2005; 366: 665–675

Sensitivity and specificity of biochemical tests for diagnosis of pheochromocytoma

	Sensitivity	Specificity
Plasma-free metanephrine	99	89
Plasma catecholamine	84	81
Urinary catecholamine	86	88
Urinary-fractionated metanephrines	97	69
Urinary total metanephrine	77	93
VMA	64	95

Jacques W M Lenders, Lancet 2005; 366: 665–675

Biochemical testing for suspected Pheochromocytoma

Test	Expected results in functional Pheochromocytoma	Comment
Plasma free metanephrines	> 2-4 X Upper limit normal range	Excellent Screening test (LC- MS/ MS)
24-hour urinary metanephrines		

Jacques W M Lenders, Lancet 2005; 366: 665–675

Bilateral Adrenal Incidentalomas ~10%

- Both lesions assessed at time of diagnosis as for unilateral lesions
  - *Benign or malignant*
- Clinical and Biochemical screening as that of unilateral lesions with addition of
  - *Congenital adrenal hyperplasia (CAH) - 17 OHP*
  - *EXCLUDE ADRENAL INSUFFICIENCY*
- Surgery indications same as for unilateral mass
  - *Can consider resection of dominant mass*
- Higher rates of metastases , Cortisol excess , Pheochromocytomas, CAH and adrenal insufficiency

Four key issues that dictate management of Adrenal Incidentaloma

Is mass malignant or benign ?

- Assessing the risk of malignancy

Is mass functioning or non-functioning ?

- What functioning tumors to work up for
- How to define and manage autonomous cortisol secretion (subclinical Cushing's)

Who should have surgery ?

What follow up is recommended if surgery is not performed ?

Adrenal Incidentaloma

Asses in parallel

Potentially Malignant?

***Non-Contrast CT**
*If uncertain
consider FDG- PET,
MRI with chemical shift

Functionally active

*Clinical assessment
*1mg Dexamethasone supp test
*Plasma or Urinary metanephrines
*Aldosterone/ Renin ratio
(Only in pts with HTN or ↓Potassium)
*Sex Hormone and steroid precursors
(Only in pts with suspected Adrenal Ca)

Adrenal Incidentaloma

Asses in parallel

Potentially Malignant?

***Non-Contrast CT**
*If uncertain
consider FDG- PET,
MRI with chemical shift

Functionally active

*Clinical assessment
*1mg Dexamethasone supp test
*Plasma or Urinary metanephrines
*Aldosterone/ Renin ratio
(Only in pts with HTN or ↓Potassium)
*Sex Hormone and steroid precursors
(Only in pts with suspected Adrenal Ca)

Discuss in Multidisciplinary team

Incidentally Discovered Adrenal Mass

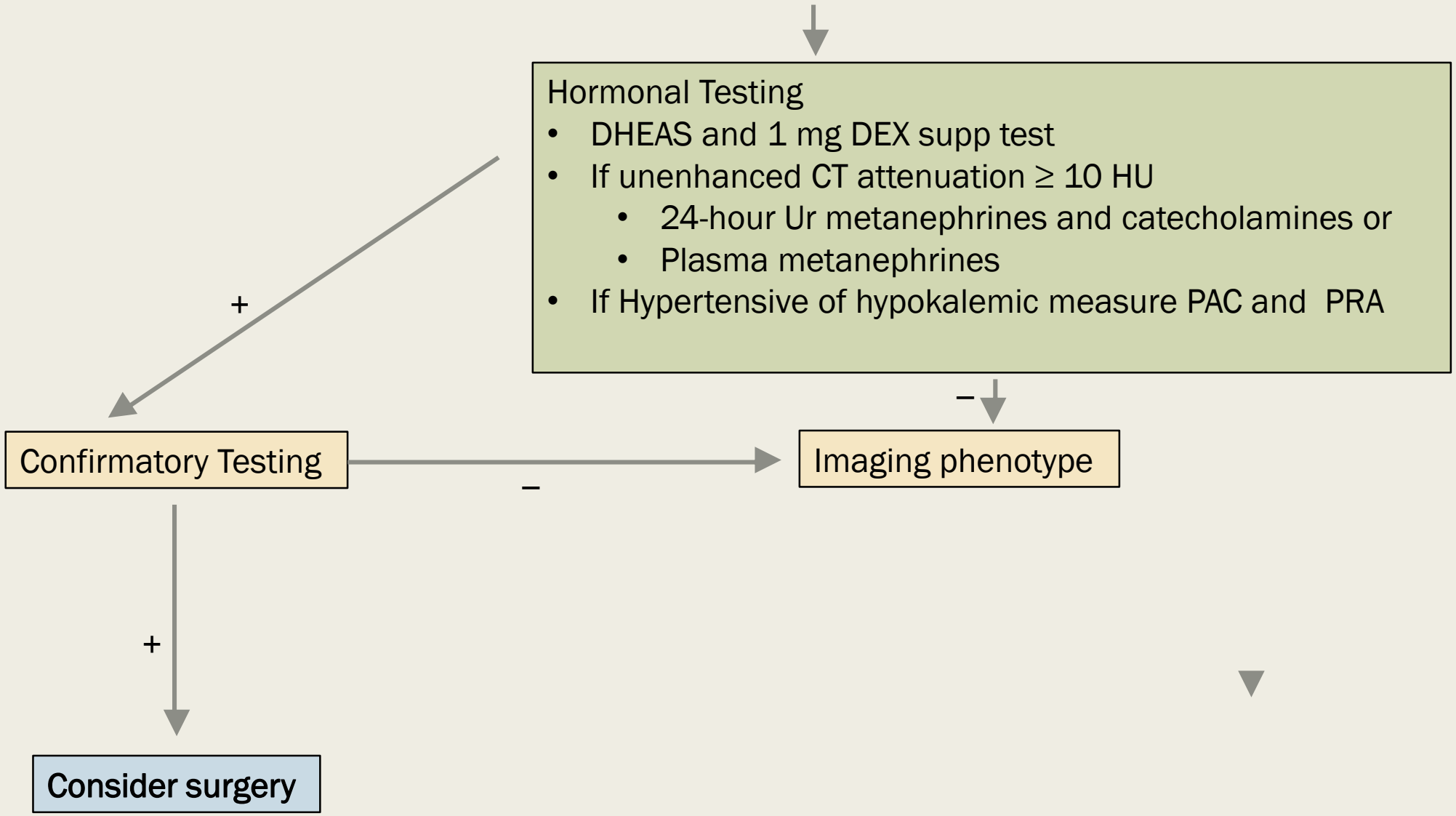

Young WF Jr. Clinical practice . The incidentally discovered adrenal mass . NEJM 2007; 356(6):601-610

Incidentally Discovered Adrenal Mass

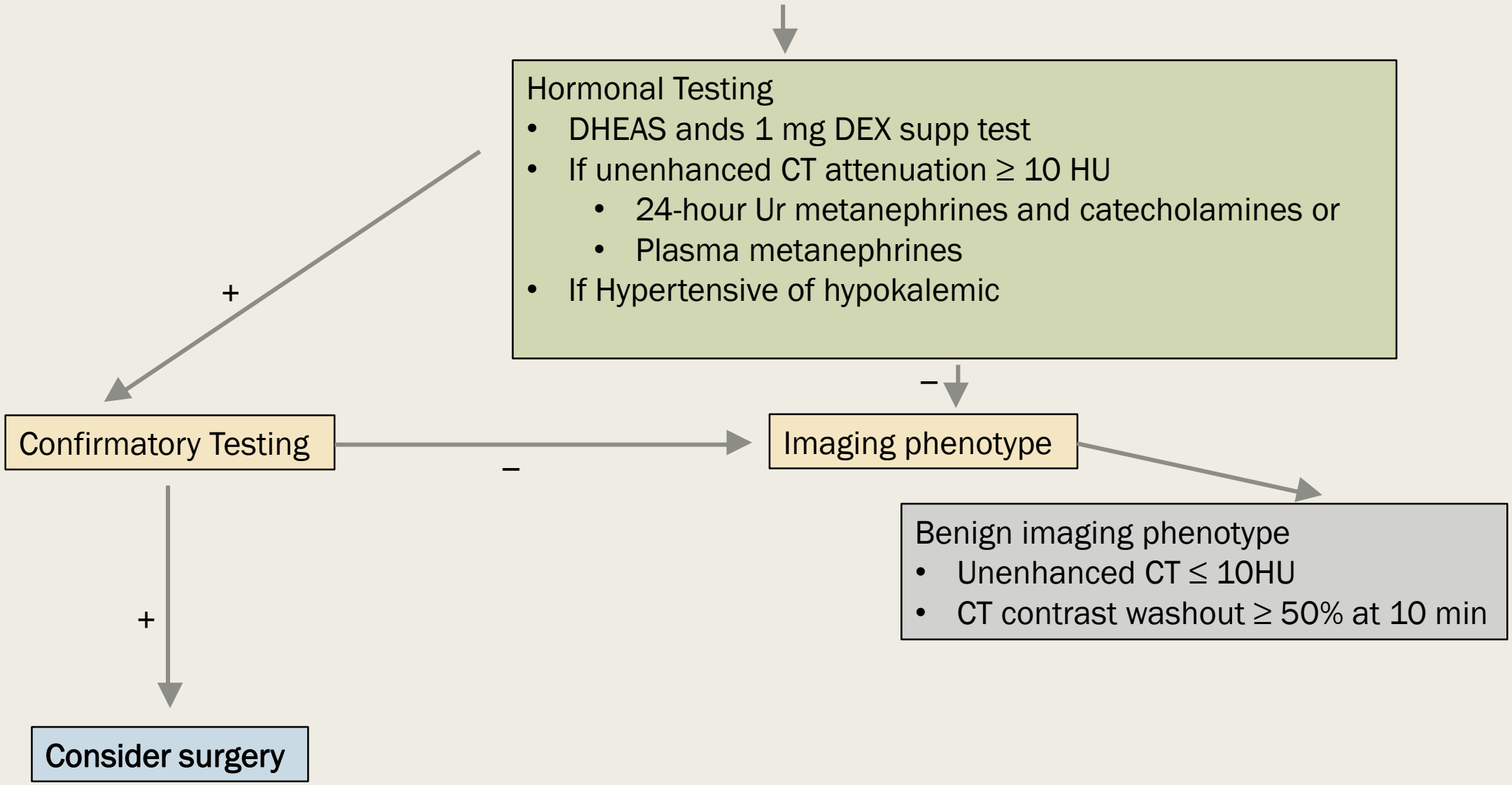

Young WF Jr. Clinical practice . The incidentally discovered adrenal mass . NEJM 2007; 356(6):601-610

Incidentally Discovered Adrenal Mass

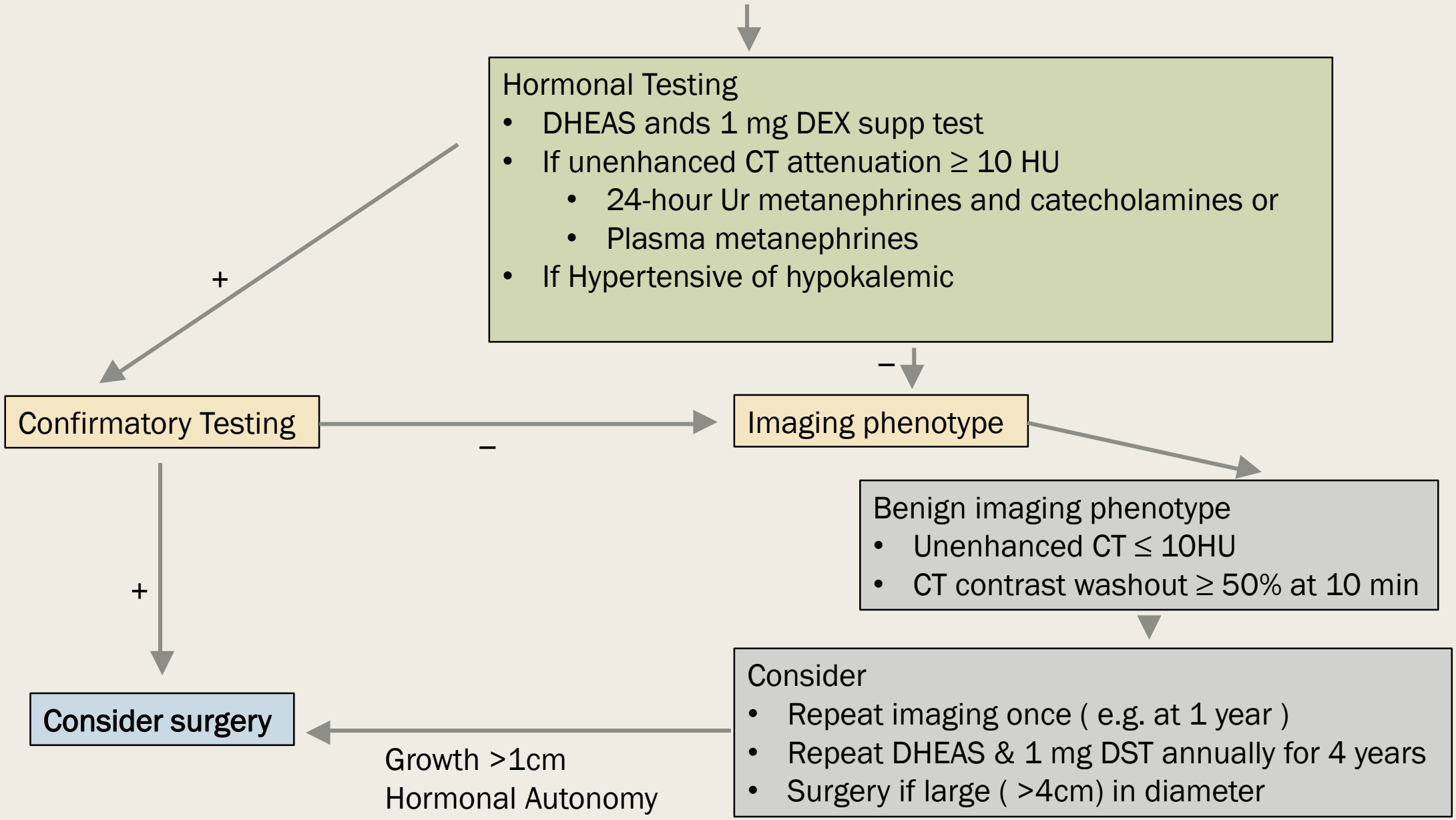

Young WF Jr. Clinical practice . The incidentally discovered adrenal mass . NEJM 2007; 356(6):601-610

Adrenal mass and history of extra adrenal malignancy

- CT sensitivity of HU <10 and size <4 cm 93% (vs 100 %)
- Adrenal mass is a met in 75% cases
  - ***Primary Cancer Lung, Renal, Breast or Melanoma***
  - ***25% cases adrenal mass NOT METASTATIC***
  - *Exclude Pheochromocytoma in all cases*
  - *FDG – PET may be relevant*
  - *Adrenal lesions deemed benign require no further work up*
- Biopsy ??

Indications of FNAC – Very Rare !!

- Main indication for adrenal biopsy is to confirm diagnosis of extra adrenal metastasis
- Only if **ALL** of the following criteria are met
  - *The lesion is not conclusively benign on imaging*
  - *The lesion is hormonally inactive*
    - Pheochromocytoma excluded
  - *Outcome will affect therapeutic strategy*

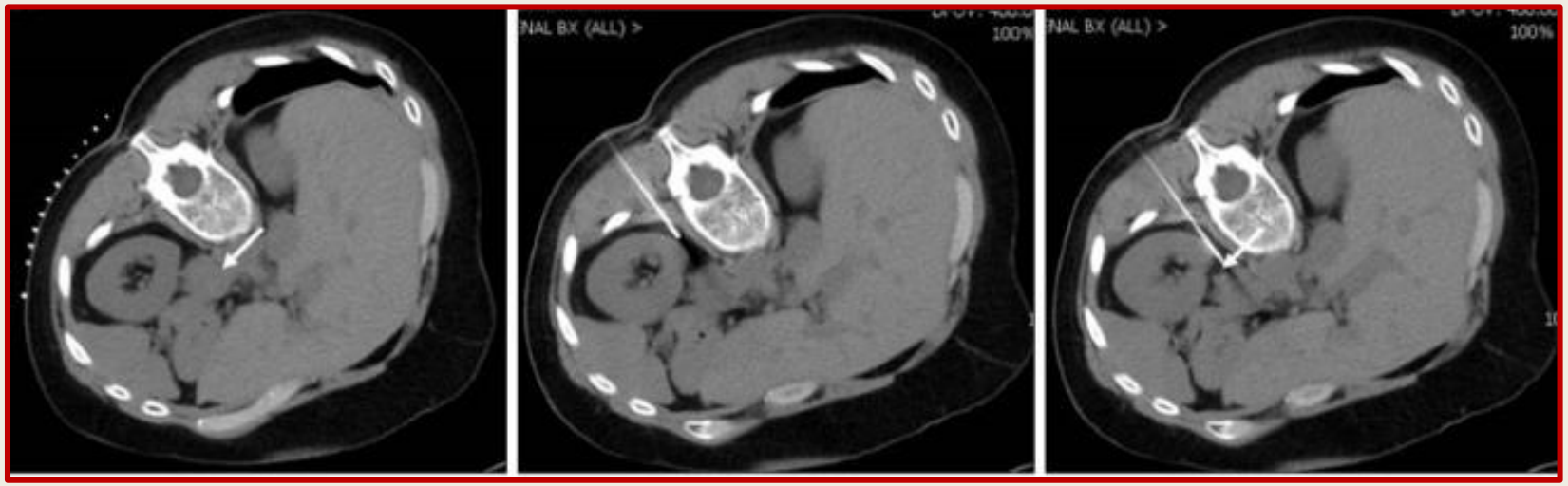

Pt with Melanoma

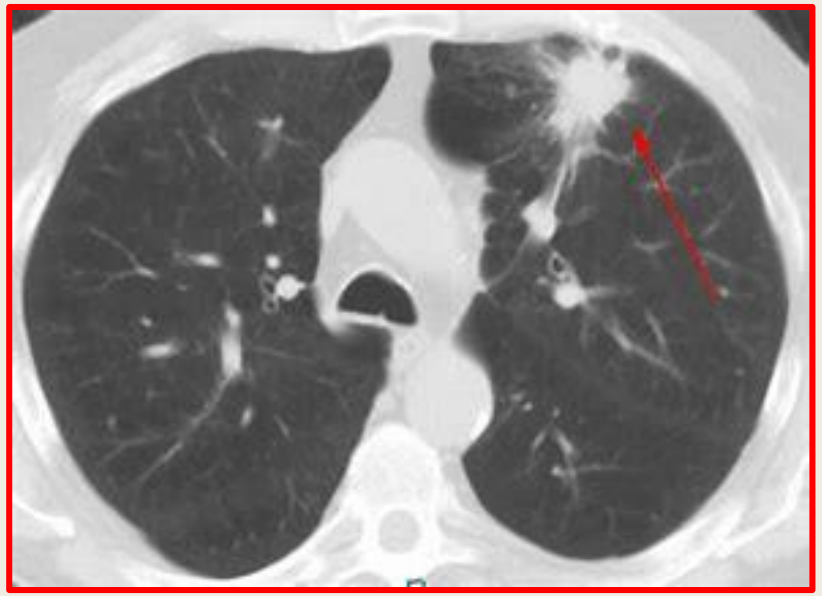

Pt with Lung Cancer and adrenal Metastasis

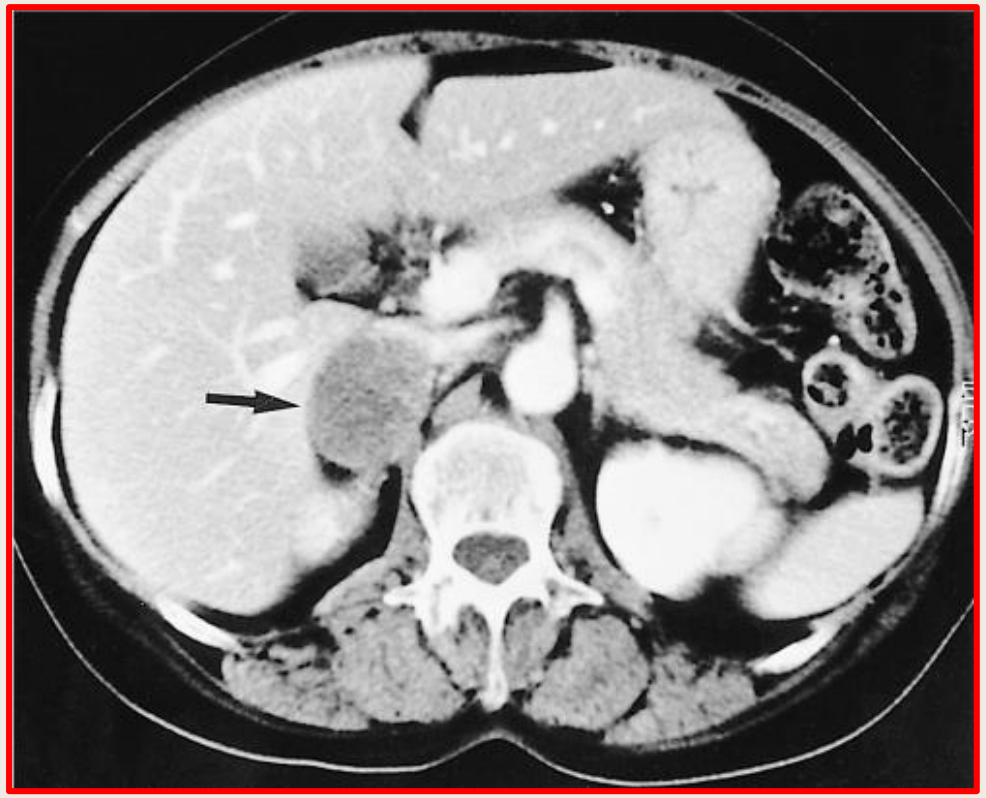

Incidentally Discovered Adrenal Mass

Hormonal Testing
- DHEAS ands 1 mg DEX supp test
- If unenhanced CT attenuation ≥ 10 HU
  - 24-hour Ur metanephrines and catecholamines or
  - Plasma metanephrines
- If Hypertensive of hypokalemic

+

Confirmatory Testing

–

Imaging phenotype

–

Benign imaging phenotype
- Unenhanced CT ≤ 10HU
- CT contrast washout ≥ 50% at 10 min

+

Consider surgery

Consider
- Repeat imaging once (e.g. at 1 year)
- Repeat DHEAS & 1 mg DST annually for 4 years
- Surgery if large (>4cm) in diameter

Suspicious imaging phenotype
- Unenhanced CT attenuation >20 HU
- CT contrast washout <50% at 10min

Consider
- FNA Biopsy is suspected mets or infection
- Surgery (sp if <60 years)
- Close FU (e.g. repeat imaging at 3 months

Young WF Jr. Clinical practice . The incidentally discovered adrenal mass . NEJM 2007; 356(6):601-610

Follow up

If the non contrast CT is consistent with benign adrenal mass

- Hz<10 (<20) , homogenous lesion and <4 cm – NO FURTHER IMAGING

“Indertiminate masses “

- FU in 6-12 months with imaging
- Surgical resection if grows > 20% growth (or at least 5mm-1cm growth in one dimension)
- Additional imaging if surgery not done (6-12 months)

Except in patients with autonomous cortisol hypersecretion avoid repeat hormone testing unless clinically indicated

- New onset Diabetes / Hypertension worsening

Annual retesting for autonomous cortisol secretion

- 3-4 years suggested

Conclusions

- Adrenal Incidentalomas are common and increase with age
- Management requires multidisciplinary team approach
- If unenhanced CT <10Hu , homogenous and < 4 cm
  - *no further workup/ imaging for malignancy needed*
- Incidence of malignancy is low – Risk higher in tumors >6 cm
- Biopsy rarely indicated (only if it changes staging and management)
- Functioning tumors
  - *Pheochromocytoma 7-10%*
  - *Conn's (Hyperaldosterone) 2%*
  - *Cortisol hypersecretion 10%*
    - *Avoid using the term "Subclinical Cushing's "*